Fishhead Labs, LLC
Cherished Pet Autopsy & Discovery Services
Pathology Consulting Services
cpads.fishheadlabs@gmail.com

Submitted by:
Dr. Rebecca Klipin
2707 Biscayne Blvd.
Miami, FL 33137

Facility: Veterinary Emergency Group, Miami

Accession #: F26-099
Received: 03/06/2026
Finalized: 3/28/2026
Patient ID: 3o93nl6c
Name: "Oreo" Wang
Species: Feline (Ragdoll)
Sex: Female/S
Age: 7 years

Autopsy Full Report

Submission:

Received for autopsy was a cream and gray, 5.7 kg, female spayed, Ragdoll feline **(Figure 1)**. The cat had a history of lethargy, inappetence, azotemia, glycosuria, persistent hyperkalemia, and possible small intestinal changes on ultrasound. The cat was received in good nutritional status with a body condition score of 7/9 and mild postmortem autolysis. The mucus membranes were pale pink **(Figure 1)**. The conjunctiva were swollen and edematous. Watery red fluid drained from the nares. Multiple areas of the fur were shaved including the medial hindlimbs, abdomen, and right cervical skin. Two sutures were placed in the left cervical skin. Yellow tinged subcutaneous fluid expanded the inguinal regions.

Entrance into the thoracic cavity was unremarkable; negative pressure was present in the thorax **(Figure 2)**. The diaphragm was intact. Approximately 20 ml of dark red non-clotted fluid was present in the thoracic cavity (7.2 g/dL). All lung lobes were diffusely mottled red and light red. On cut sections, they were wet, heavy and oozed abundant watery fluid. The trachea was filled with dark red watery fluid **(Figure 2)**. The right thyroid gland was approximately half the size of the left thyroid gland. Dark red watery fluid was noted in the pericardium. The heart weighed 19.9 g. All valves, great vessels, and cardiac muscle were intact. Scant amounts of dark red fluid was seen in the esophageal lumen.

Examination of the abdomen revealed mildly dilated intestinal tract and straw colored, 5.9 g/dL clear fluid. The gastric lumen to the proximal colon contained dark black watery to mucoid contents **(Figure 2)**. The mesenteric lymph nodes were light red and small. The pancreas had light pink homogenous lobules. The liver was light brown with sharp lobular margins. Dark green bile filled the gallbladder and the common bile duct was patent. The spleen was dark red with sharp margins.

In the retroperitoneal space, abundant adipose surrounded the kidneys. The ureters, urinary bladder, and kidneys were intact. Approximately 15 ml of pale-yellow urine was in the urinary bladder. The left kidney was slightly larger than the right kidney **(Figure 2)**. Both kidneys had pale cortices, but there was adequate corticomedullary distinction. The adrenal glands were bilaterally symmetrical.

The skull was intact with no evidence of trauma. The sinus cavities were clear, but the left side had mild amounts of dark red fluid.

No additional gross abnormalities were noted in the remaining tissues.

A full set of tissues was held in 10% neutral buffered formalin for examination under the microscope. Fresh segments of liver, spleen, kidney, lung, lymph node, small intestine, and large intestine are held for ancillary testing if needed. Urine, abdominal fluid, and thoracic fluid were saved back as well.

Histopathology:

Sections of heart, thyroid glands, parathyroid glands, adrenal gland, mesenteric lymph node, lung lobes, liver, kidneys, spleen, pancreas, stomach, small intestine, and large intestine were examined for microscopic pathology. Sections of gastrointestinal tract were moderate to markedly autolyzed with loss of cellular detail. Significant changes will be delineated in the section below.

Immunohistochemistry:

1. **Parvovirus (Panleukopenia virus; sections of intestine and stomach):** The eight sections of gastrointestinal tract are immunonegative for parvovirus. There was nonspecific staining of gastric mucus cells and luminal debris.

Morphologic diagnoses:

1. **Kidneys (Figure 3):** Cortical tubular degeneration and necrosis, multifocal, acute, moderate with abundant intratubular protein, rare cellular casts, and rare refractile intratubular crystals
2. **Lung:** Pulmonary edema, diffuse, chronic mild with widespread intravascular fibrinous to fibrinohemorrhagic material (supportive of systemic disease, septicemia, or toxemia)
3. **Abdominal, thoracic, and pericardial cavities:** Moderate protein effusions, diffuse, moderate (macroscopic finding) with splenic and gastric serosal mesothelial hypertrophy (reactive microscopic finding)
4. **Gastrointestinal tract:** Intraluminal digested blood (melena), diffuse, severe (macroscopic finding with rare blood identified in the lumen histologically)
5. **Small intestine (Figure 4):** Enteritis, lymphoplasmacytic, diffuse, chronic, mild to moderate with marked autolysis (please see comments)
6. **Stomach:** Gastritis, lymphofollicular and lymphocytic, multifocal, chronic, mild (marked autolysis)
7. **Large intestine:** Colitis, lymphocytic, diffuse, chronic, mild with marked autolysis (please see comments)
8. **Lymph node (mesenteric):** Lymphoid follicular hyperplasia and lymphoid depletion, chronic, mild with sinusoidal histiocytosis, erythrocytes, and multifocal fibrinous material
9. **Liver:** Vacuolar hepatopathy (glycogenosis/hydropic and lesser lipidosis), diffuse, chronic, mild with acute (perimortem) centrilobular to diffuse congestion
10. **Pancreas (Figure 5):** Pancreatitis and peri-dochitis, lymphocytic, multifocal interstitial, chronic, mild
11. **Left nasal cavity:** Presumptive red tinged edema fluid (macroscopic finding)
12. **Left cervical subcutaneous tissue:** Suture associated hemorrhage, acute, multifocal, mild (macroscopic finding)

Comment:

The cause of Oreo's presentation and decline was acute tubular necrosis which was supportive of an acute tubular injury (and acute kidney failure), as identified clinically. This is a nonspecific reaction pattern to a variety of nephrotoxic insults and can be due to ischemic injury due to obstruction, shock and hypotension, neoplasia, or infections. In Oreo, there was no significant renal inflammation (including no evidence of underlying chronic interstitial nephritis), no evidence of an infection, obvious obstruction, or neoplasia. Ischemia due to hypovolemia and shock was considered, associated with her grossly identified melena, her clinically described initial presentation with hematemesis, and her

underlying gastrointestinal disease. Unfortunately, her gastrointestinal pathology was difficult to characterize due to the presence of marked autolysis with loss of cellular detail and variable loss/sloughing of the superficial mucosa in all segments of examined gastrointestinal tract. There was discernible mild to moderate lymphoplasmacytic lamina propria inflammation in all gastrointestinal segments and lymphofollicular aggregates in the stomach, findings supportive of chronic gastritis and enteropathy a nonspecific finding that can be associated with immune mediated factors, dietary intolerance or indiscretion, bacterial overgrowth, parasitism, or combinations thereof.

Overt evidence of neoplasia, ulceration/erosion, perforation, obstruction, hemorrhage, necrosis, uremic mineralization, or infectious agents were not apparent in her gastrointestinal tract. However, an ulcerative/erosive process not identified and sampled during the postmortem gross examination, or not identified histologically due to the extensive autolysis, was possible and cannot be ruled out. Immunohistochemistry (IHC) for parvovirus (feline panleukopenia virus) was pursued to further investigate for this highly infectious potential cause of the grossly identified melena. All tested sections of the gastrointestinal tract were immunonegative.

An intrinsic or extrinsic coagulopathy was considered for the diffuse gastrointestinal hemorrhage in Oreo. Abnormal clotting (and eventual hemorrhage if clotting occurs over a long period and with consumption of clotting factors) due to acute tubular injury and decreased kidney function can occur. Based on the degree of renal cortical tubular necrosis present and the lack of obvious tubular epithelial cell regeneration, I suspect that her renal tubular injury occurred after her initial presentation of hematemesis and was not the cause of her gastrointestinal hemorrhage. There were no identified fibrin thrombi, vascular changes, or other areas of ischemic damage to support her having renal failure associated hypercoagulability. Another intrinsic aberration of the clotting cascade was considered unlikely with hemorrhage restricted to the gastrointestinal tract and with no other history of abnormal hemorrhage outside of the recent presentation. The grossly identified dark red fluid within Oreo's lungs and left nasal cavity was initially suspected to be hemorrhage. Histologically, in the lung sections, this fluid was confirmed to be edema fluid that was likely red tinged due to autolysis with no identified pulmonary hemorrhages, or significant hemorrhages in other examined tissues. Ingestion of an anticoagulant was considered as this can cause hemorrhage isolated to one organ system with minimal tissue changes.

In dogs and cats, primary nephrotoxic differentials include ethylene glycol metabolites (antifreeze; rare crystals were seen histologically), lilies, antimicrobials (i.e. aminoglycosides, sulfonamides), chemotherapeutic agents (i.e. cisplatin, doxorubicin), heavy metals, vitamin D, venoms, and grapes/raisins (in dogs). Endogenous substances, including bile, hemoglobin, and myoglobin can also result in acute tubular injury. There was no evidence of any of these endogenous toxins in Oreo's examination. If there is a toxic substance of reasonable suspicious based on history of exposure, then testing for this substance with fresh/frozen tissue would be an option. There is no gold standard test for analysis and verification of lily toxicity. The most positive confirmation involves the observation of the animal ingesting the lily, compatible clinical symptoms, compatible clinicopathologic findings, and supportive postmortem lesions in cats that die (including the observation of ingested plant material within the gastrointestinal tract (not identified in Oreo's case), not just nephrotoxic tubular necrosis). Onset of anuric renal failure occurs 18-24 hours after exposure. Both the leaves and flowers are reportedly toxic.

Toxicology testing options include a mass spectrometry toxicant general screen, which can detect a wide variety of toxicants (including ethylene glycol) but is not highly sensitive for some compounds and is often inconclusive, or more specific and directed toxin testing, if there is a history or exposure to a specific confirmed toxin in her environment (including an anticoagulant screening). Fresh tissues (kidney and/or liver) have been saved if you would like to pursue toxin testing. Please contact the laboratory for additional information or if you would like to pursue any toxicology testing in this case. All toxicology tests are done through an outside laboratory with shipping costs plus any accession fees and the cost of the testing, for these outside laboratory tests.

In her liver, there was histologic evidence of mild hepatocellular vacuolar degeneration which was a mixture of hydropic/glycogenic and lesser lipidosis subtypes. The most common cause of hepatic lipidosis in cats is a primary disease process causing anorexia, particularly in an over conditioned cat. Environmental stress and diet changes can precede anorexia. Some cases are idiopathic. Other differentials include metabolic disturbances (such as diabetes mellitus) and less likely toxic injuries. Oreo's pancreatic islets where within normal limits and her recent work up was not suggestive of diabetes. Hepatic glycogenosis is nonspecific and could result from a number of underlying intra or extrahepatic causes, including, but not limited to, endocrine disease (no obvious gross abnormalities identified in endocrine organs), low grade chronic toxin exposure, chronic low grade cholestasis, chronic drug administration (e.g. barbiturate therapy), or any condition associated with chronic stress (greater than 4 weeks duration). Chronic infections and neoplasia fall into the latter category. There was no evidence of hepatitis or other primary hepatobiliary pathology in Oreo's examined liver. The cause of these vacuolar changes is unknown.

Oreo had mild lymphocytic inflammation in the interstitium of her pancreas and around pancreatic ducts, consistent with mild chronic pancreatitis. Mild pancreatitis is commonly identified histologically in feline patients. However, this does not always correlate with clinical disease and in many cats can be an incidental finding of unknown clinical relevance. Oreo had no evidence of acute pancreatitis, and the relevance of the mild lymphocytic infiltrates is unknown. Histologically, one of Oreo's thyroids was slightly larger than the other, this was interpreted as being within normal limits with no identified nodular expansion, inflammation, or neoplasia. The examined section of adrenal gland was within normal limits.

Oreo's heart was within normal limits with no identified histologic or gross abnormalities. There was no evidence of feline infectious peritonitis in the examined tissues. The tricavitary effusion was presumed to be due acute tubular injury with no other identified cause. The remainder of the findings were secondary to the described pathologies, were incidental, aging, and/or perimortem changes. Please contact me if you have any questions, if you would like to discuss this case, or if you would like to pursue toxicologic testing. We are sorry for the loss of your loved one and greatly appreciate being part of their afterlife care.

Fresh frozen tissues will be retained for 3 months post autopsy date; additional targeted ancillary testing can be requested during this time. Photomicrographs and text are for report purposes only and not intended for use in publications or for reproduction of any kind without written consent from the author.

References:

Boysen, SR. 2009. Gastrointestinal hemorrhage. Small animal critical care medicine. 30: 566-570.

Cianciolo, RE and FC Mohr. 2016. Urinary system: Chapt 4 in Jubb, Kennedy, and Palmer's Pathology of Domestic Animals, 6th edition. Editor: Maxie MG, St. Louis, MO: Elsevier; Vol 2.: 376-464.

Forman, MA. et al. 2021. ACVIM consensus statement on pancreatitis in cats. JVIM 35:703-723.

Reported by:

Susan B. Fogelson, MS, DVM, PhD, Dipl. ACVP
CEO: Fishhead Labs, LLC
Cherished Pet Autopsy & Discovery Services (CPADS)

Lani R. Bower, MA, DVM, Dipl. ACVP
Associate Pathologist, Fishhead Labs, LLC
Cherished Pet Autopsy & Discovery Services (CPADS)

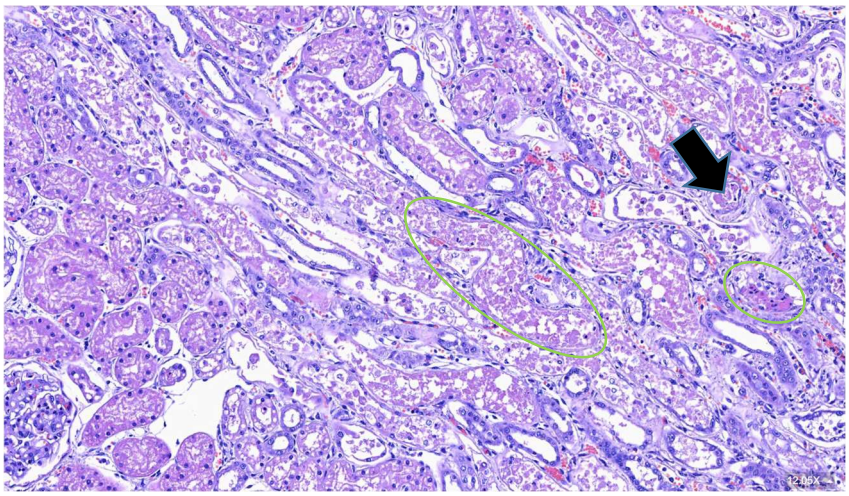

Figure 3. Photomicrograph of the kidney. There was multifocal acute tubular necrosis and degeneration. This was characterized by proximal tubular epithelial cells that were swollen and vacuolated or sloughed, hypereosinophilic and with loss of nuclei (circles). There was frequently proteinaceous eosinophilic fluid within tubules as well as scattered tubules containing aggregated sloughed and necrotic epithelial cells (cellular casts; arrow). H&E, 121X magnification.

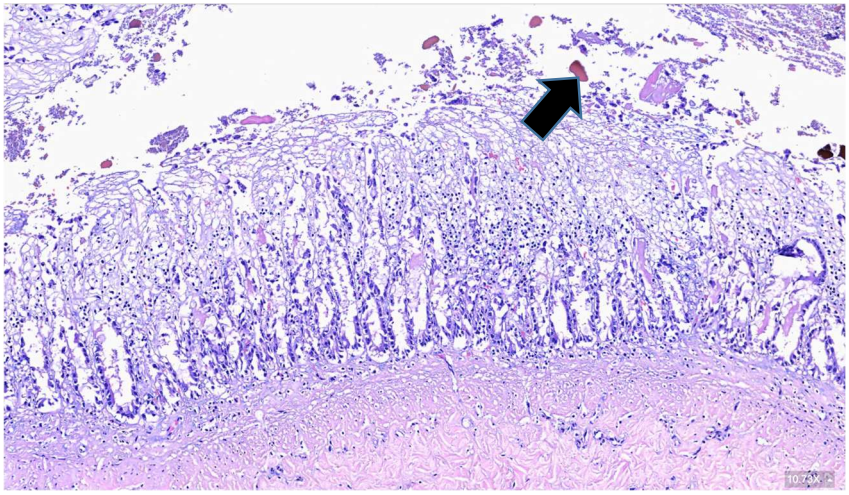

Figure 4. Photomicrograph of the small intestine. All sections of gastrointestinal tract were autolyzed with this image showing one of the more intact regions of mucosa. There were discernible lymphocytes and plasma cells within the lamina propria with faint outlines of villi but loss of cellular detail. There were aggregates of blood breakdown products in the lumen (arrow). H&E, 107X magnification.

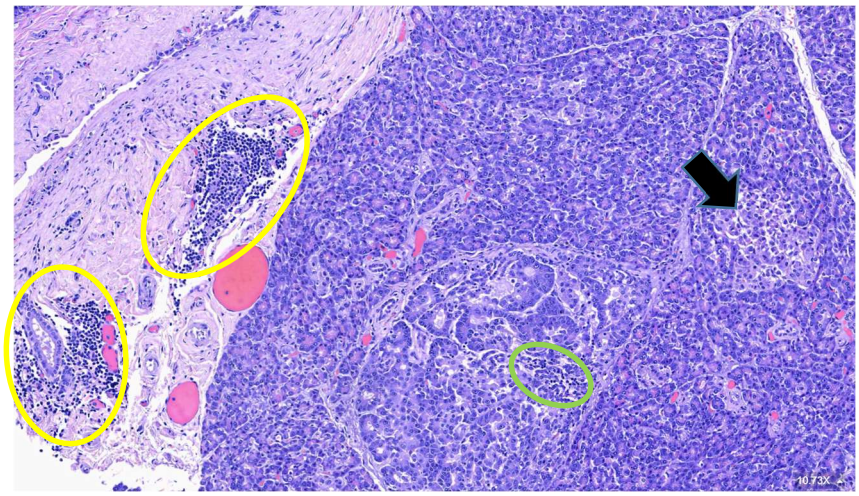

Figure 5. Photomicrograph of the pancreas. There were rare mild lymphocytic infiltrates in the exocrine pancreatic interstitium (green circle) as well as in the peripheral connective tissue, including around pancreatic ducts (yellow circles). Pancreatic endocrine islets were within normal limits (arrow). H&E, 107X magnification.